

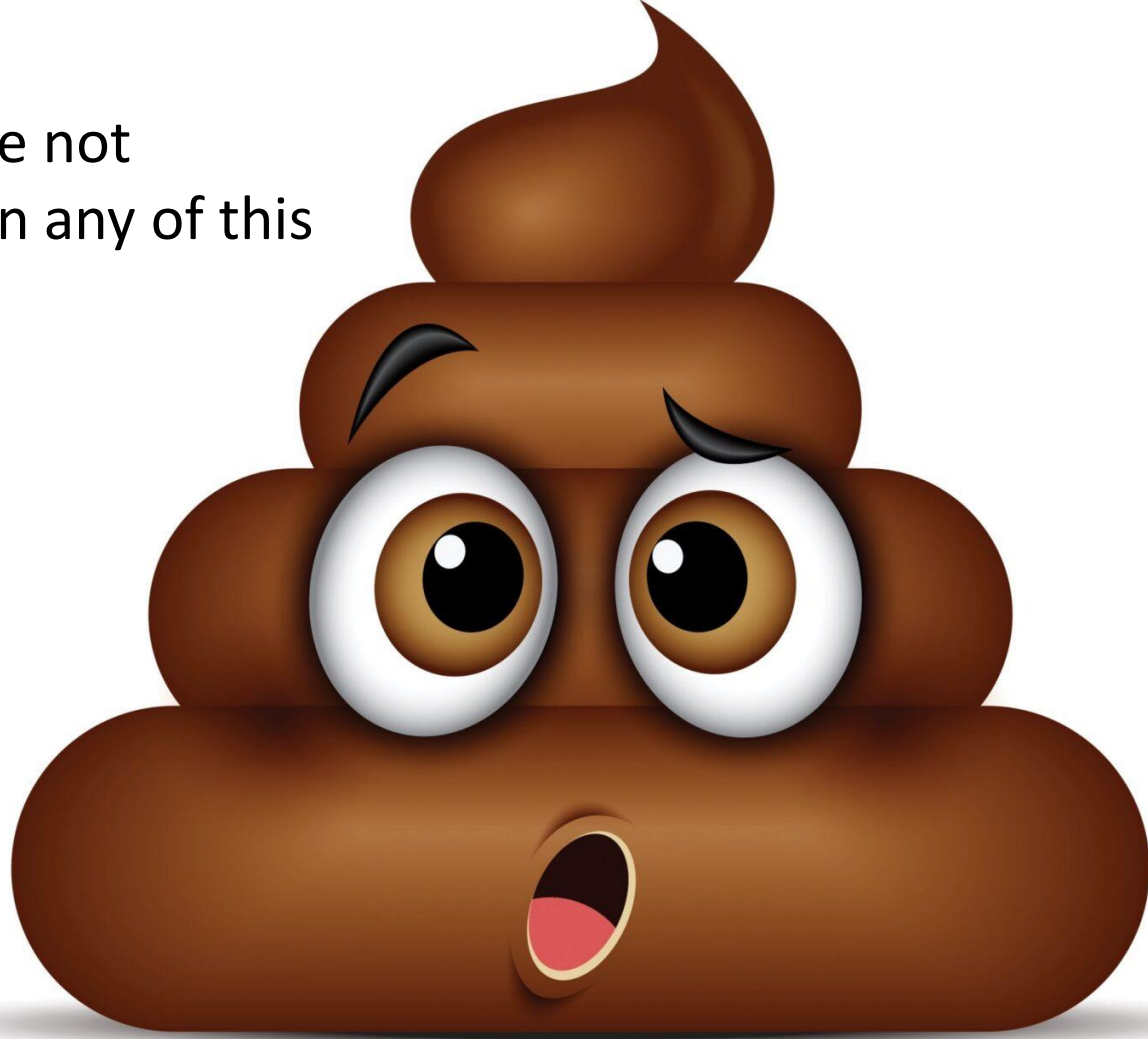

Robotic Bronchoscopy: Team Approach as Recipe for Success

Together We May Change Classic Paradigms in Thoracic Endoscopy

Rabih Bechara, MD. FCCP
Director, Interventional Pulmonology Program
Atrium/Wake Baptist
Professor of Medicine
Wake Forest School of Medicine

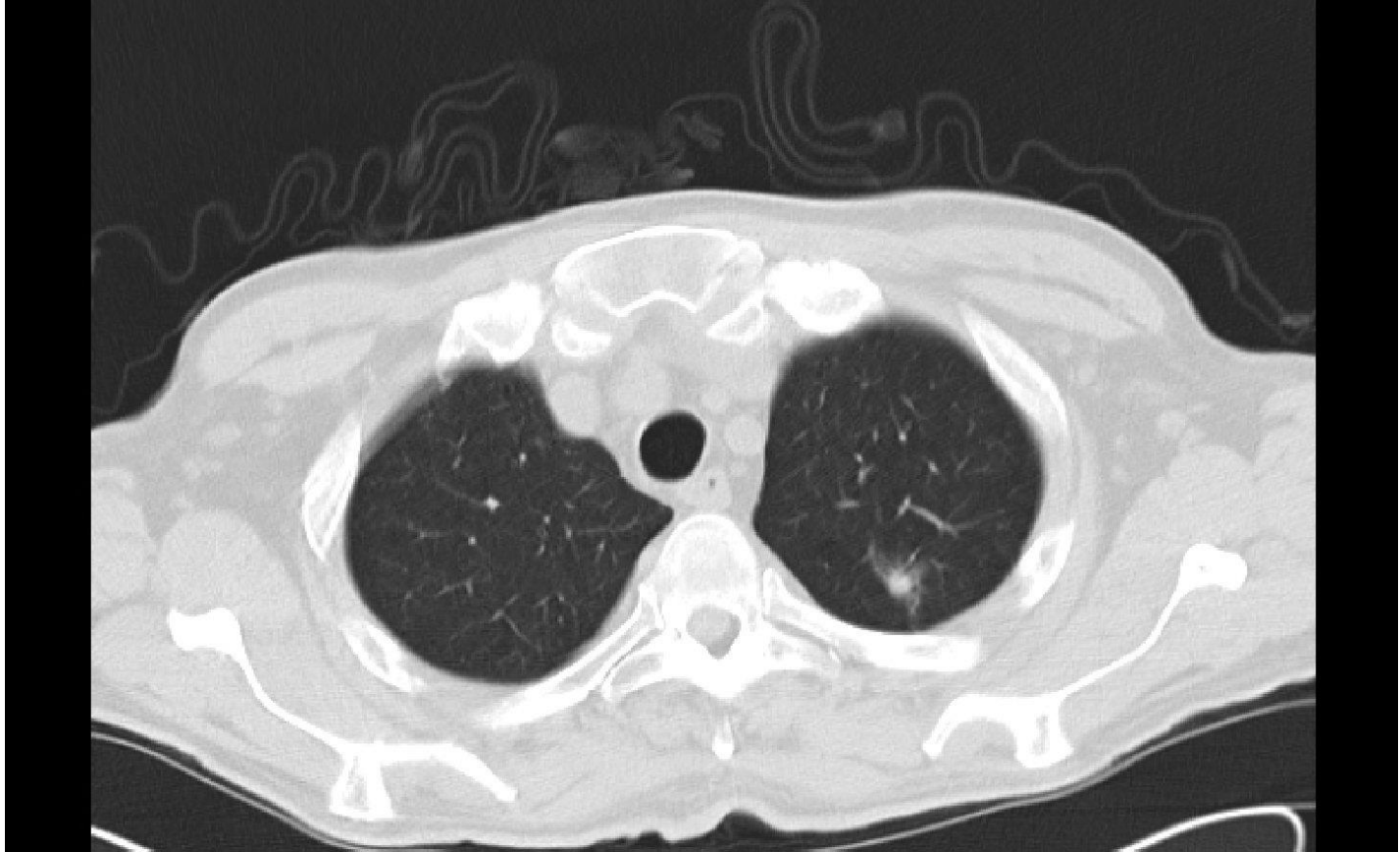
No, we are not
involved in any of this



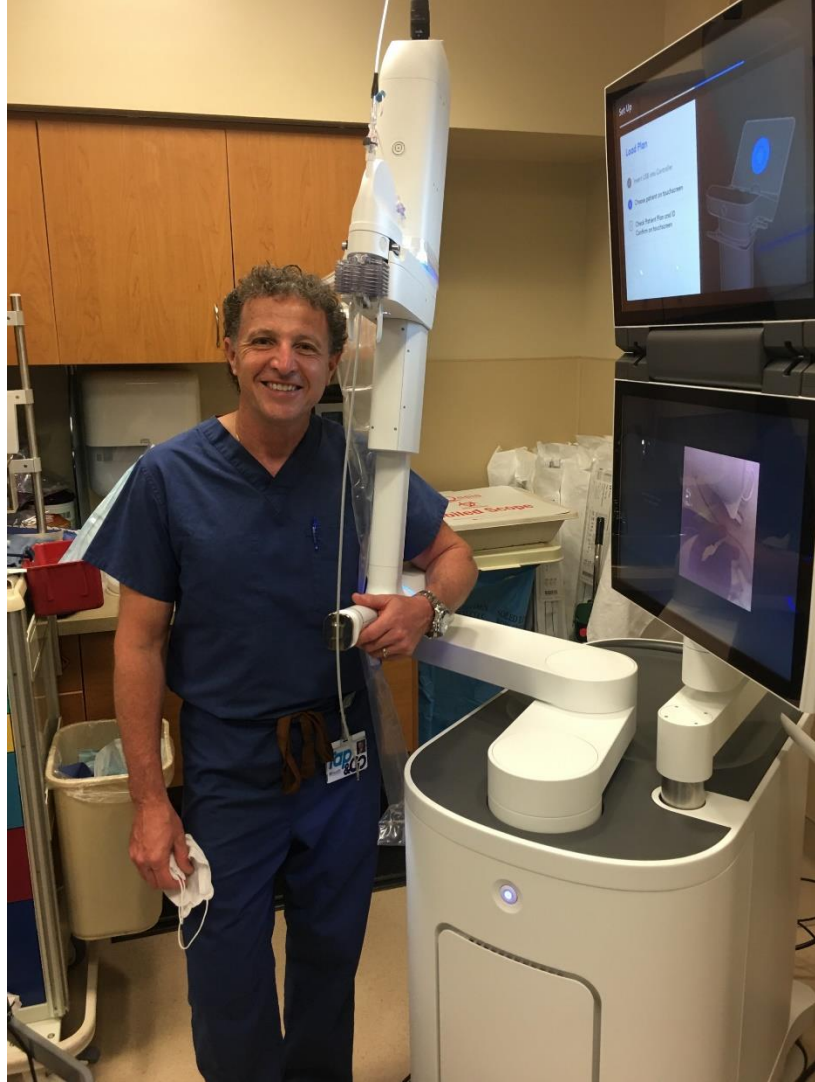Disclosures

- Intuitive: proctor
- Medtronic: research/proctor
- Olympus: research
- BD: research
- AstraZeneca: research
- Circulogene: research/speaker
- Pinnacle Biologics: research


Research sponsored trials and education grants








Because I have
EVA



With adequate technology we will



Endoscopy suite



It begins with you. Make sure the patient has stopped

- Nurse at bedside
- Anticoagulants at the right time interval
- Weight loss medications (Tirzeparide, semaglutide) at least 7 days ago !!
- Has been NPO for adequate duration
- Has a great running IV

RAKES, GARY WAYNE MR.
1953-05-11 (M) 1860179

Plan Review

100% 7:15 AM

Targets

Add Target

Identify a nodule for biopsy

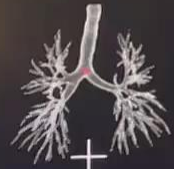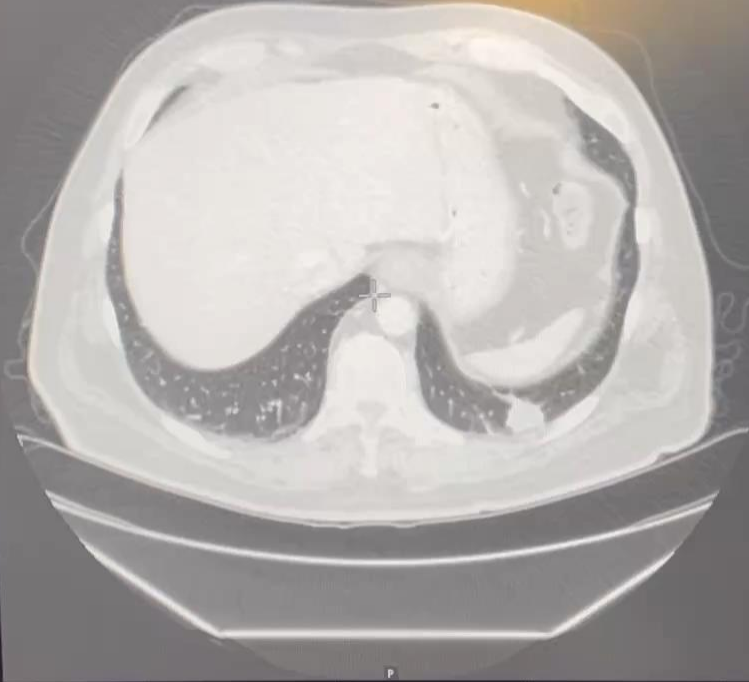
Manual Borders

Anatomy Border

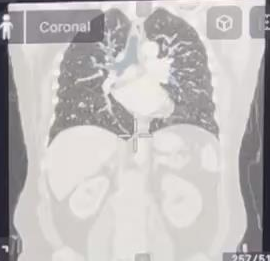Airways

Missing Airway

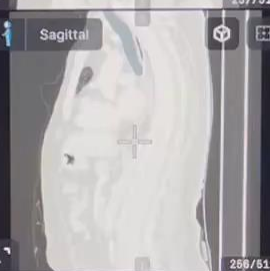Axial



Coronal



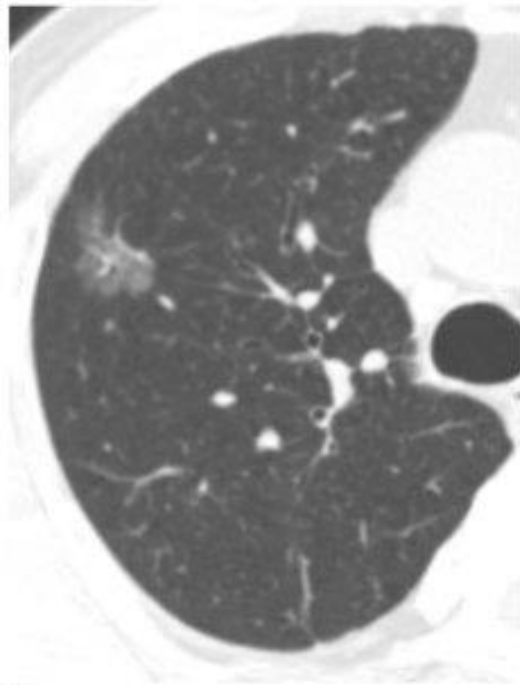
Sagittal



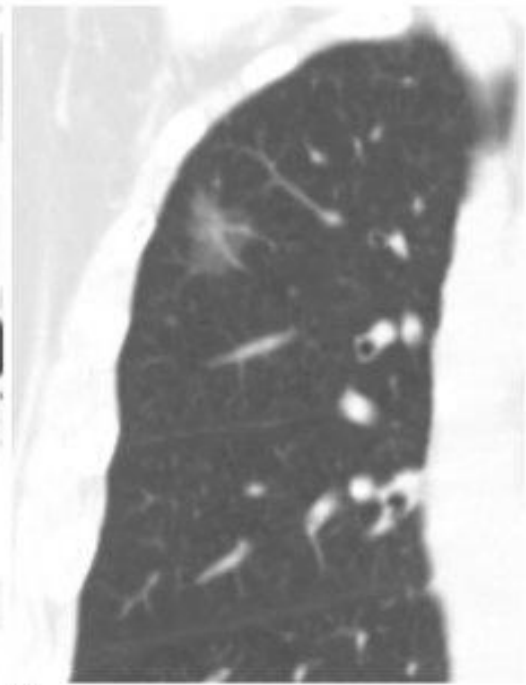
Target Focus Path Finder Reference Area Focus Sync Zoom Layout Options Layer Visibility

BRONCH

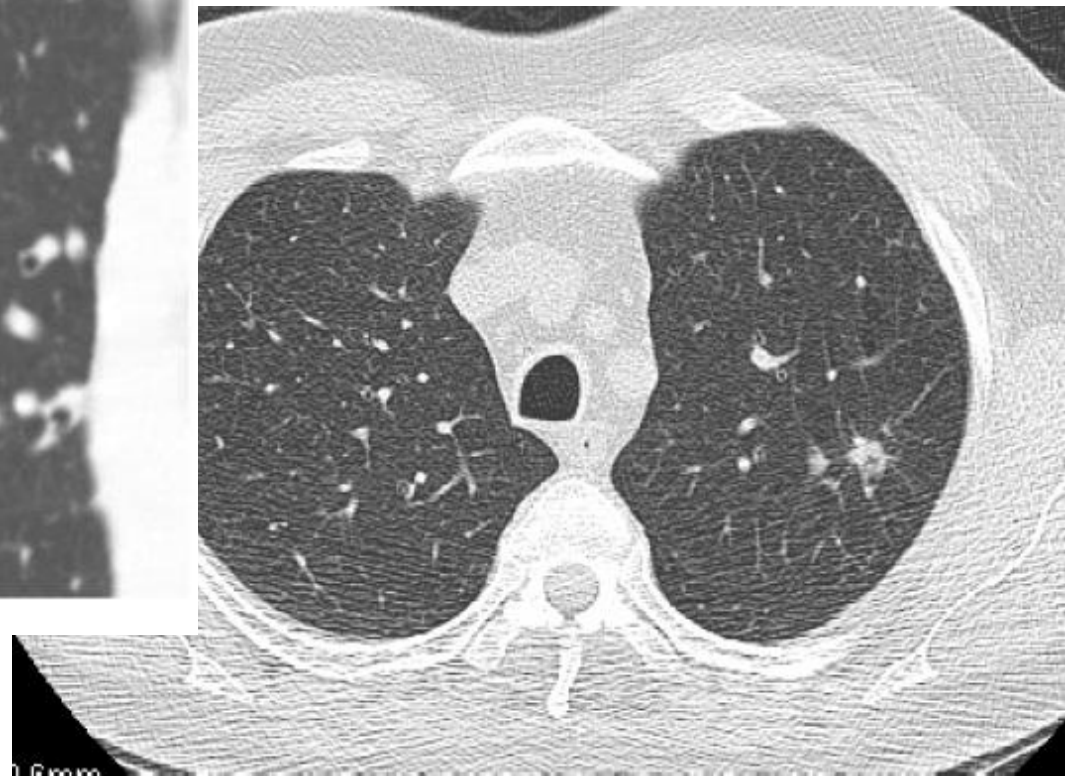
PlanPoint



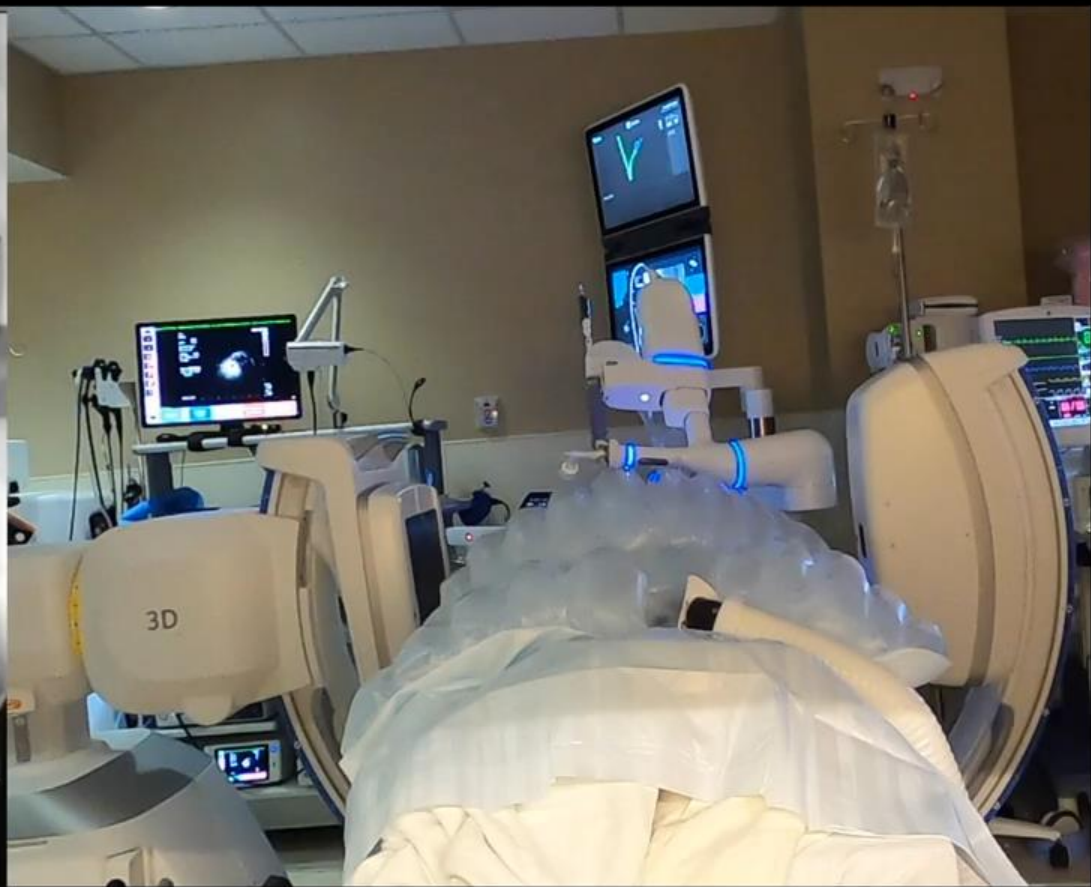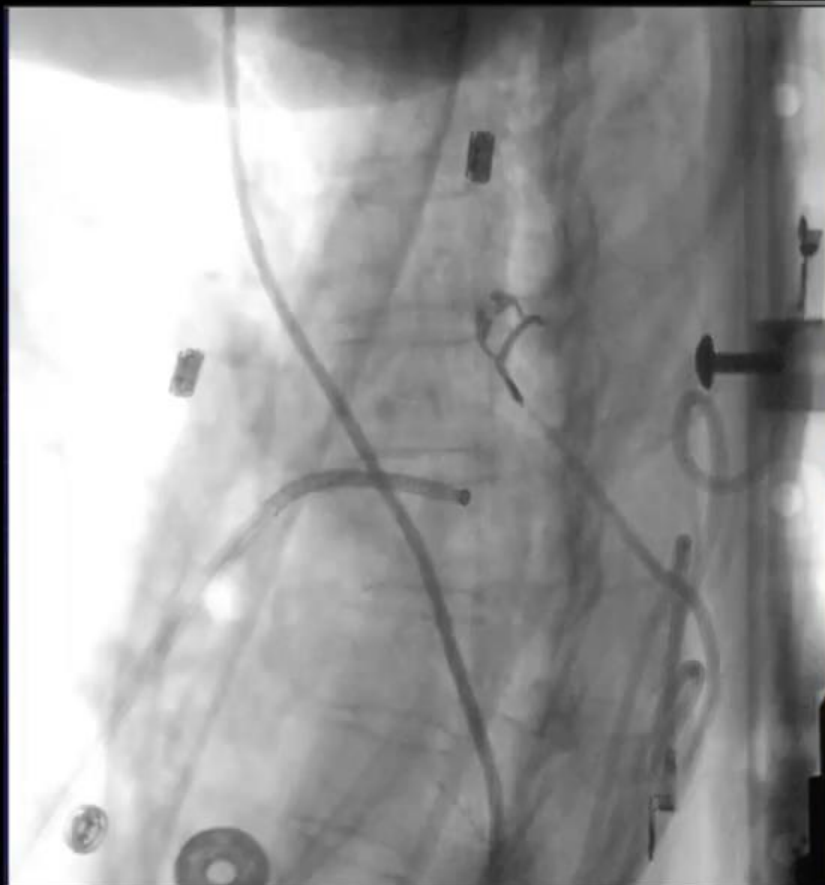
A

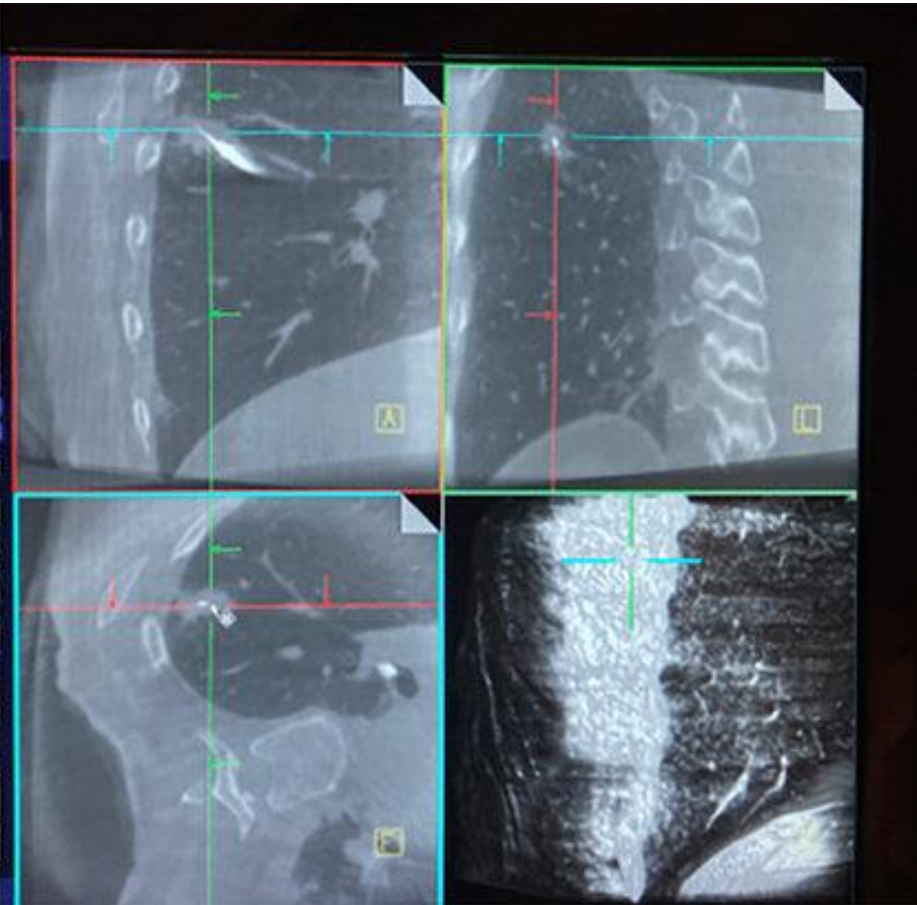
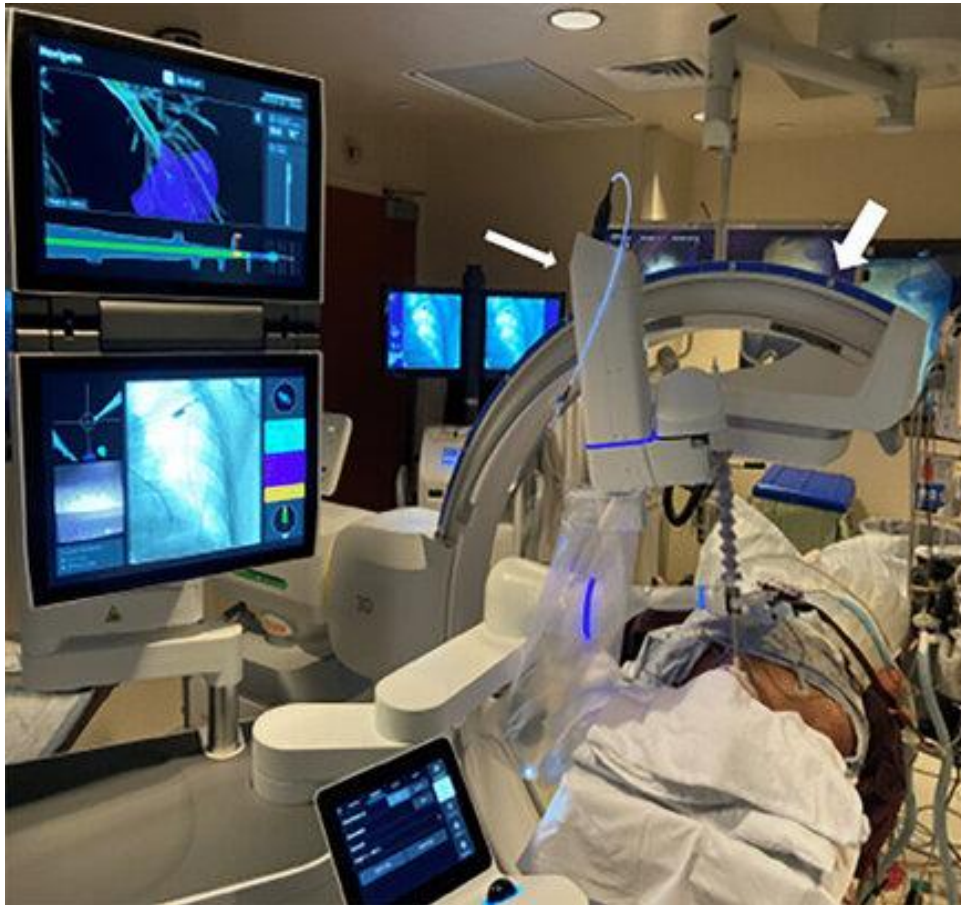

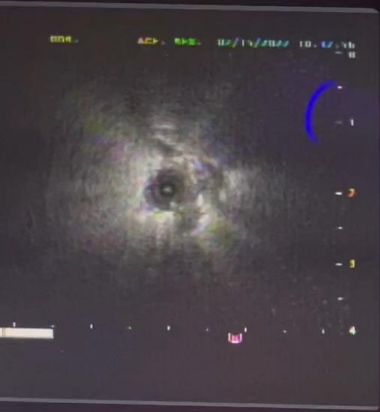
B



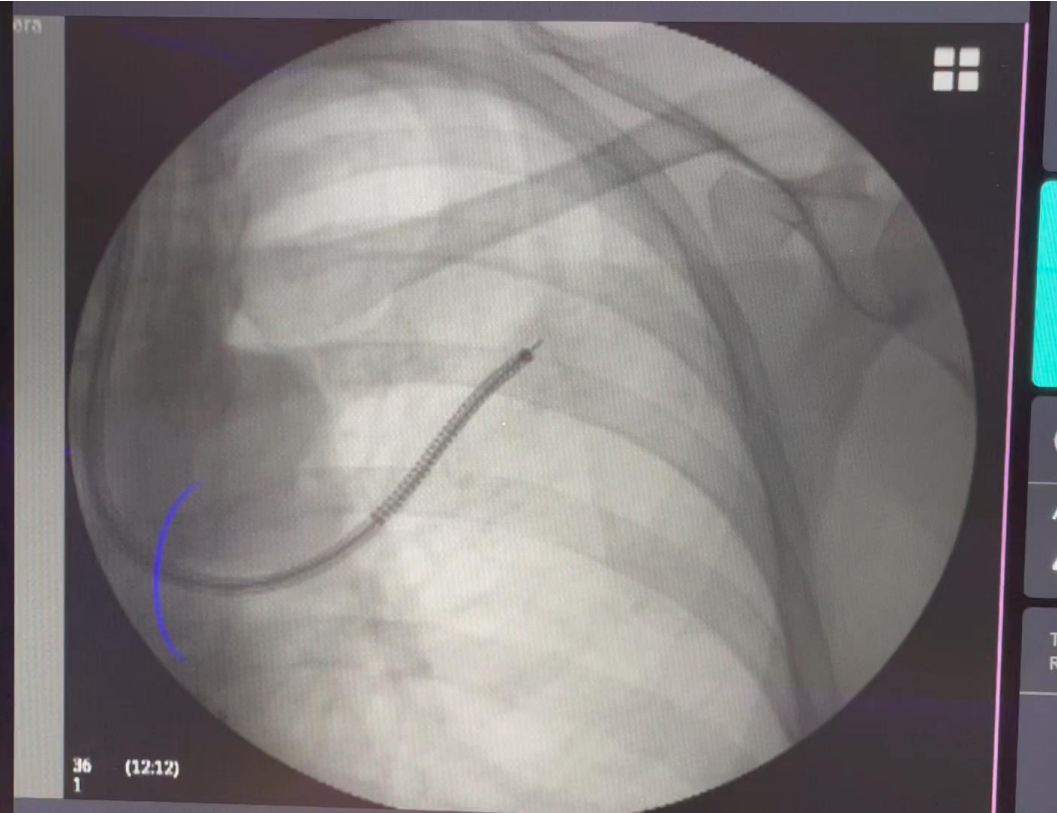
1.6 mm

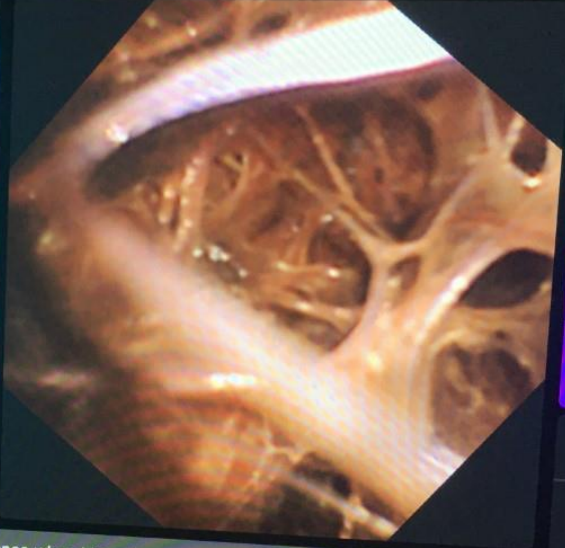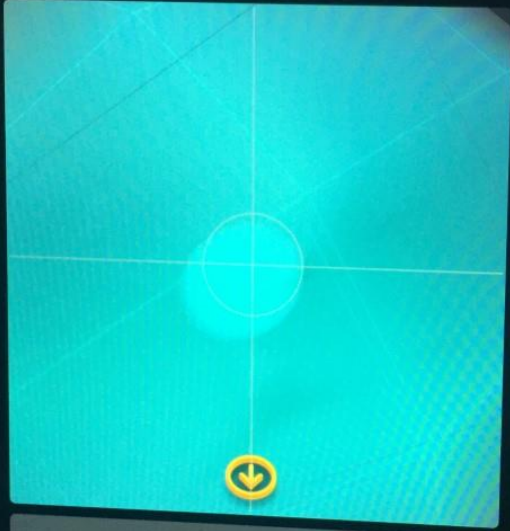






FLUORO REFERENCE





DISTANCE TO
TARGET EDGE

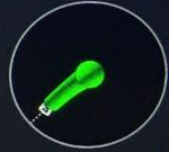
NEAR	FAR
3 MM	15

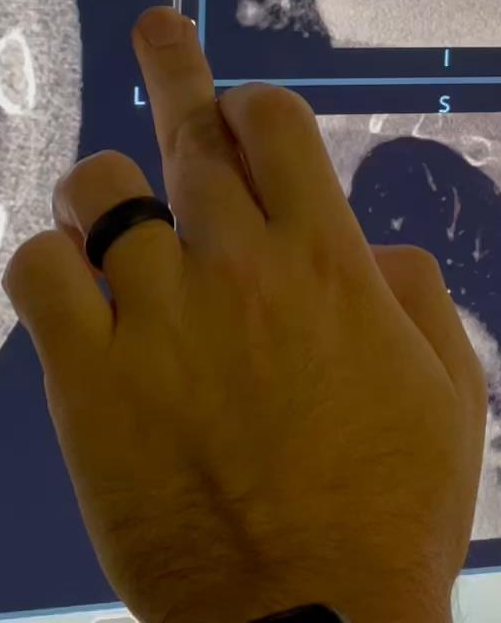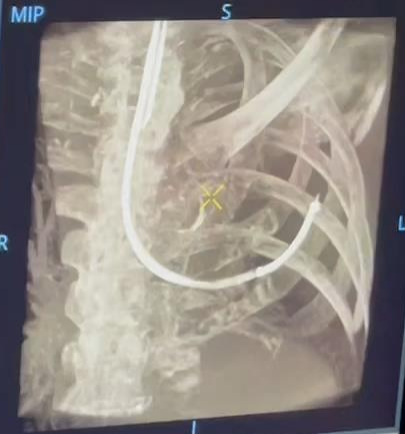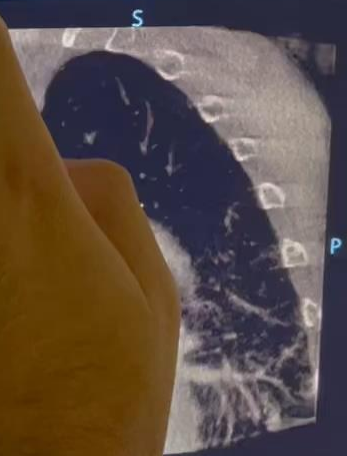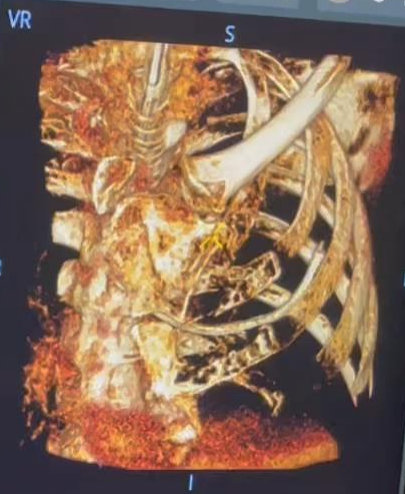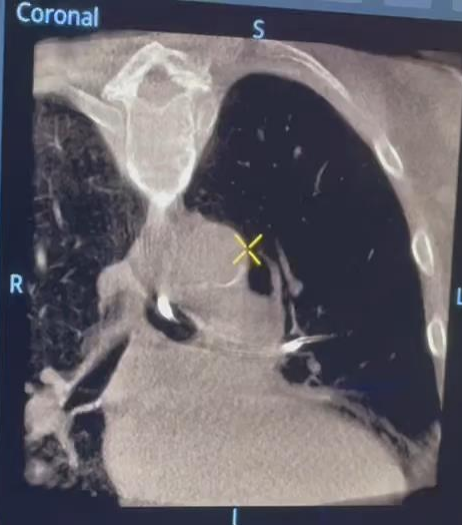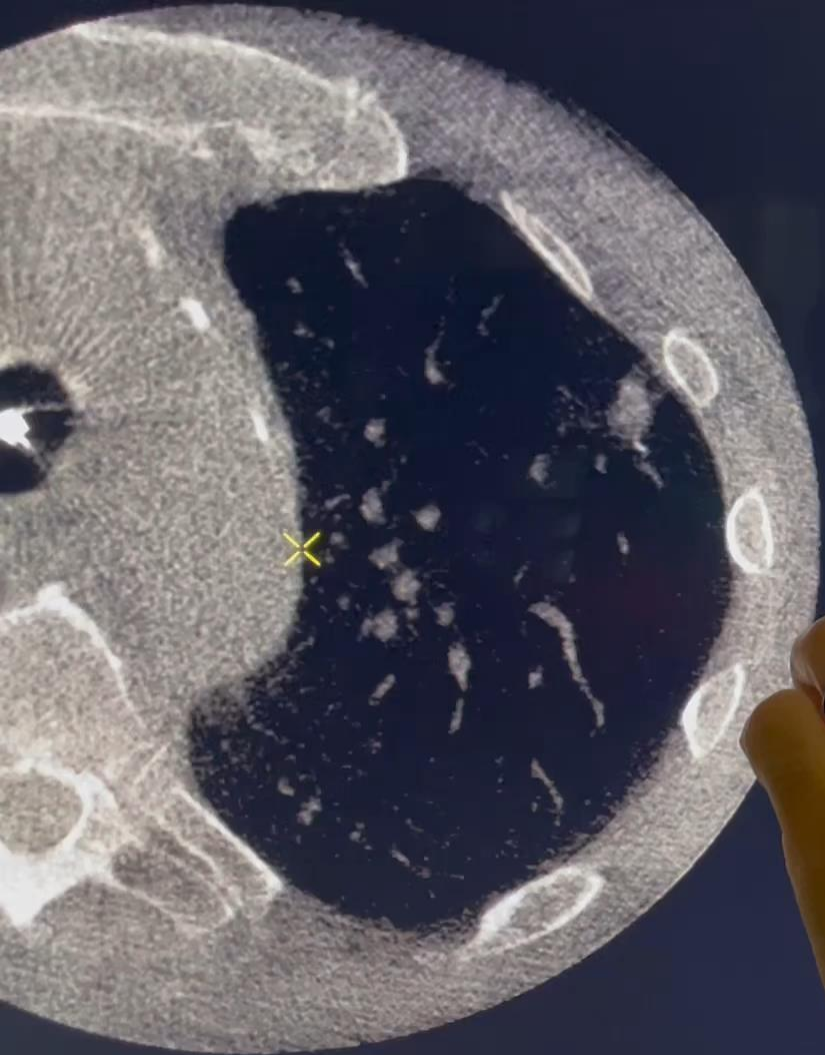
ANATOMY
BORDER

Anterior Pleural Border
21 MM

TIP BEND
RADIUS 30

Use fluoroscope guidance when biopsying





HLF

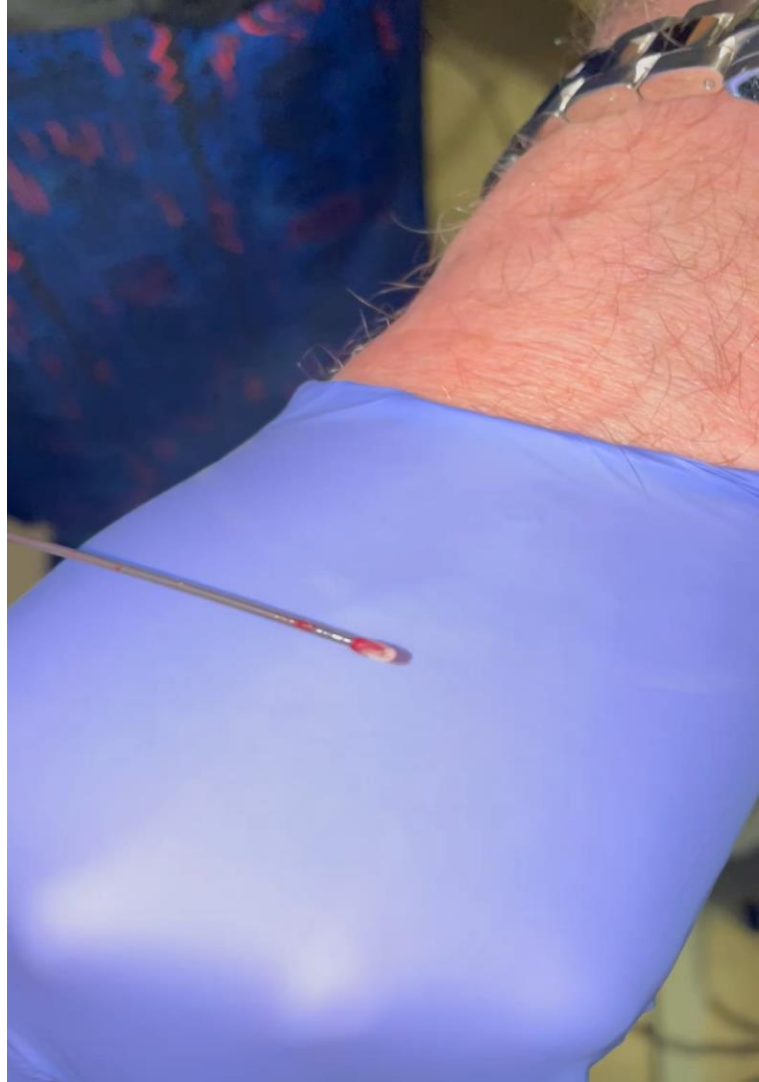
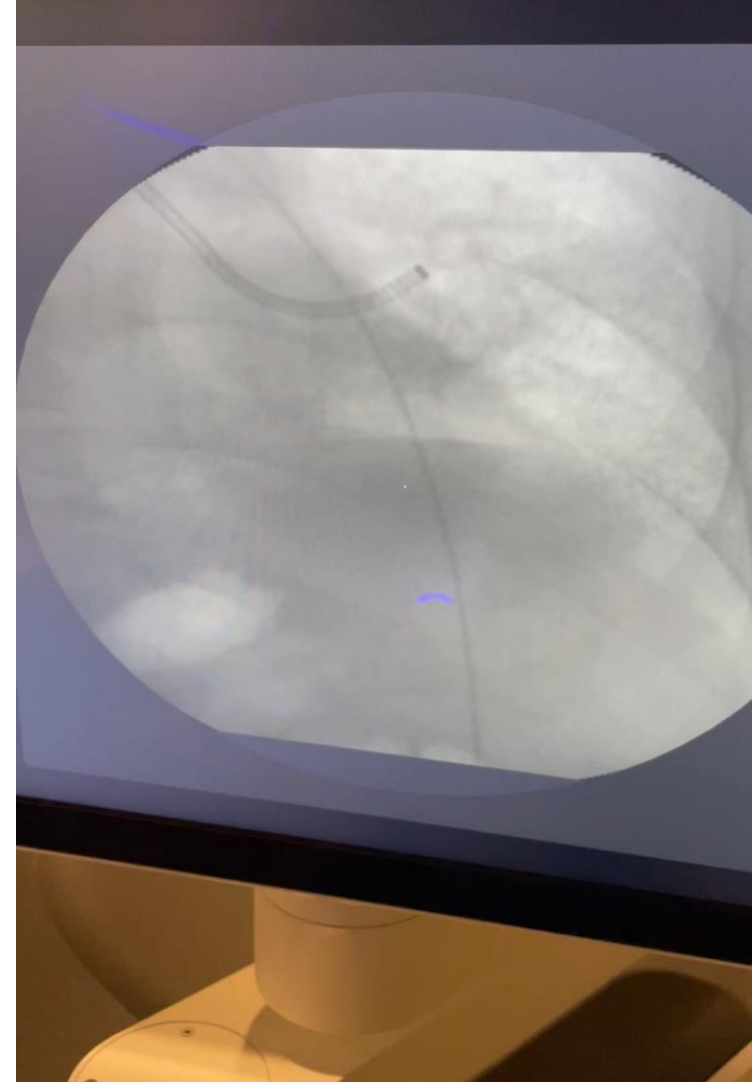15 PPS

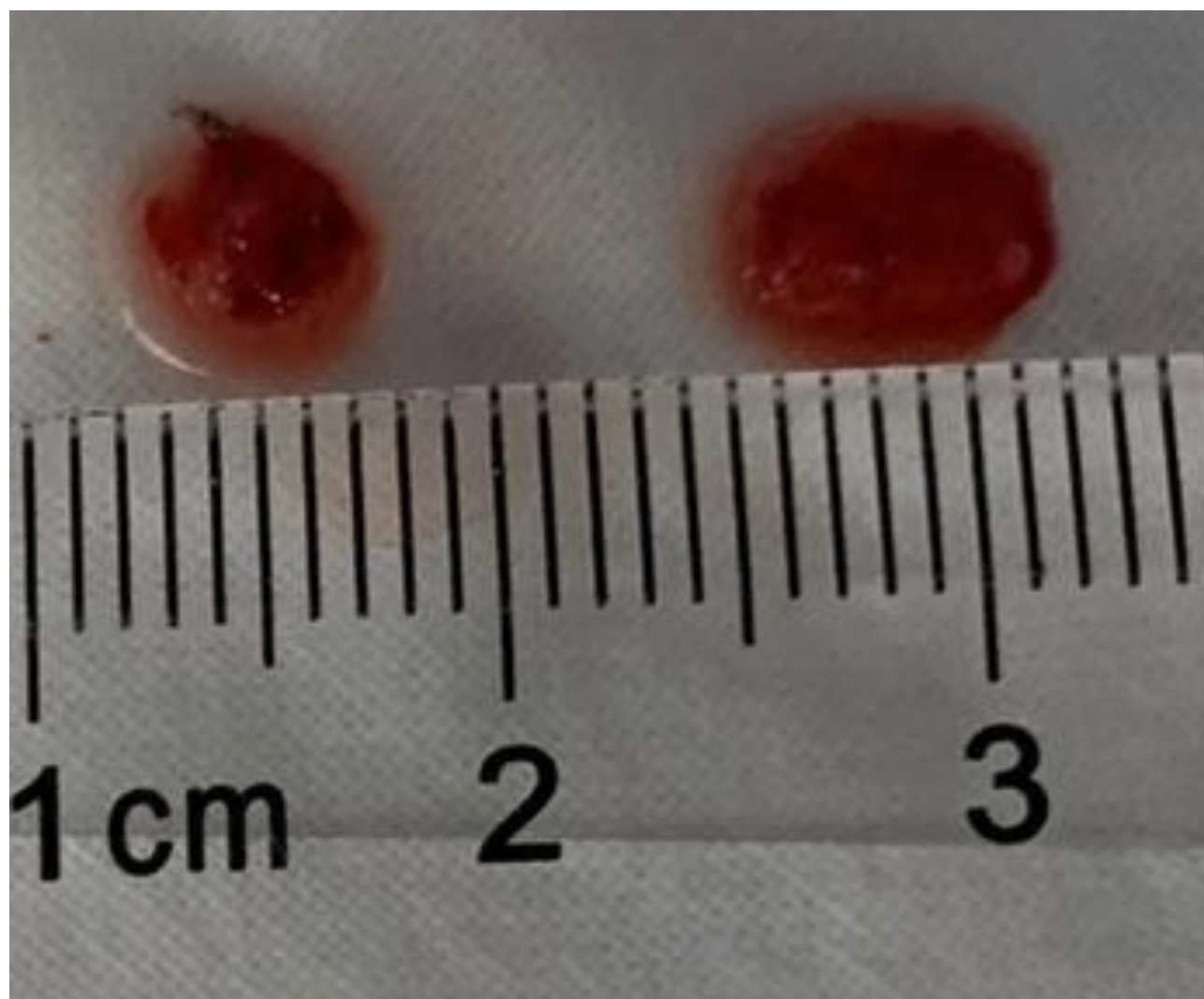
erbe
ERRELYO 2

0		
Effect	Timer	
↑ 2 ↓	4 s	
	Program	
	3 BIOPSY	

erbe

erbe





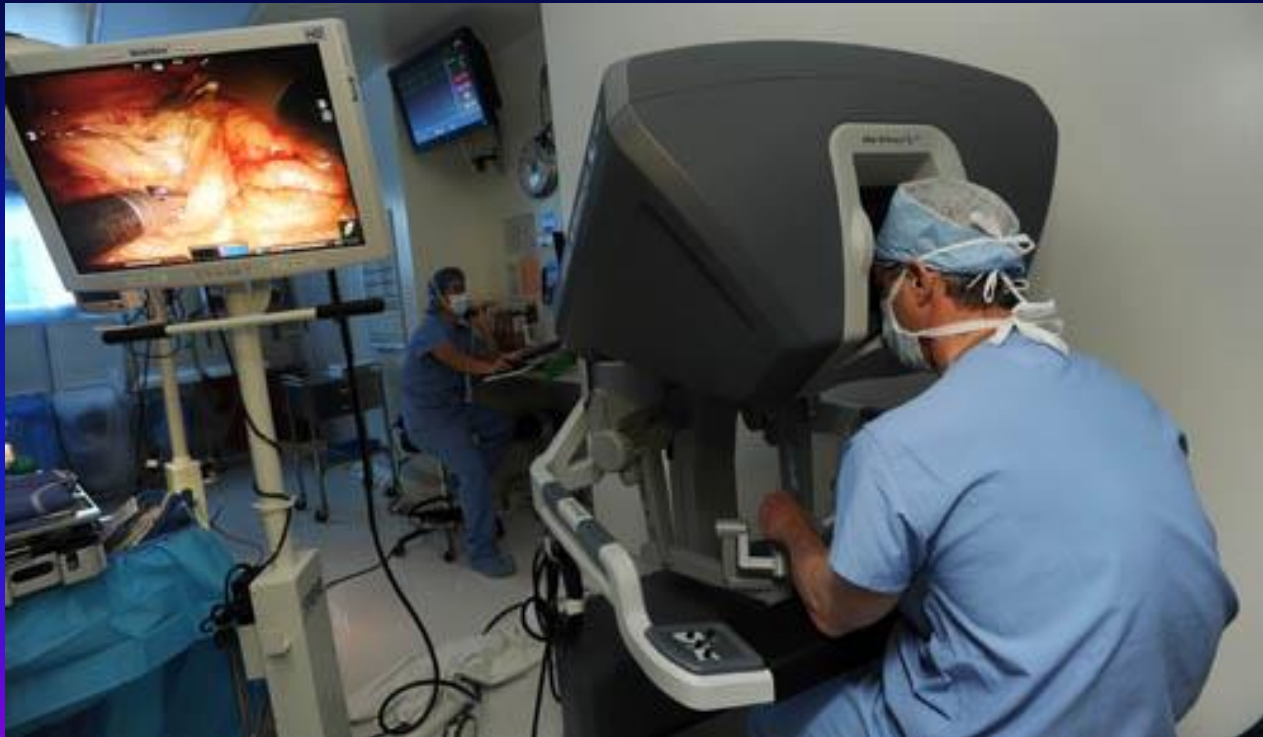In some cases, you
have to deal with an
Interventional
pulmonologist and a
thoracic surgeon at
the same time !!!!!



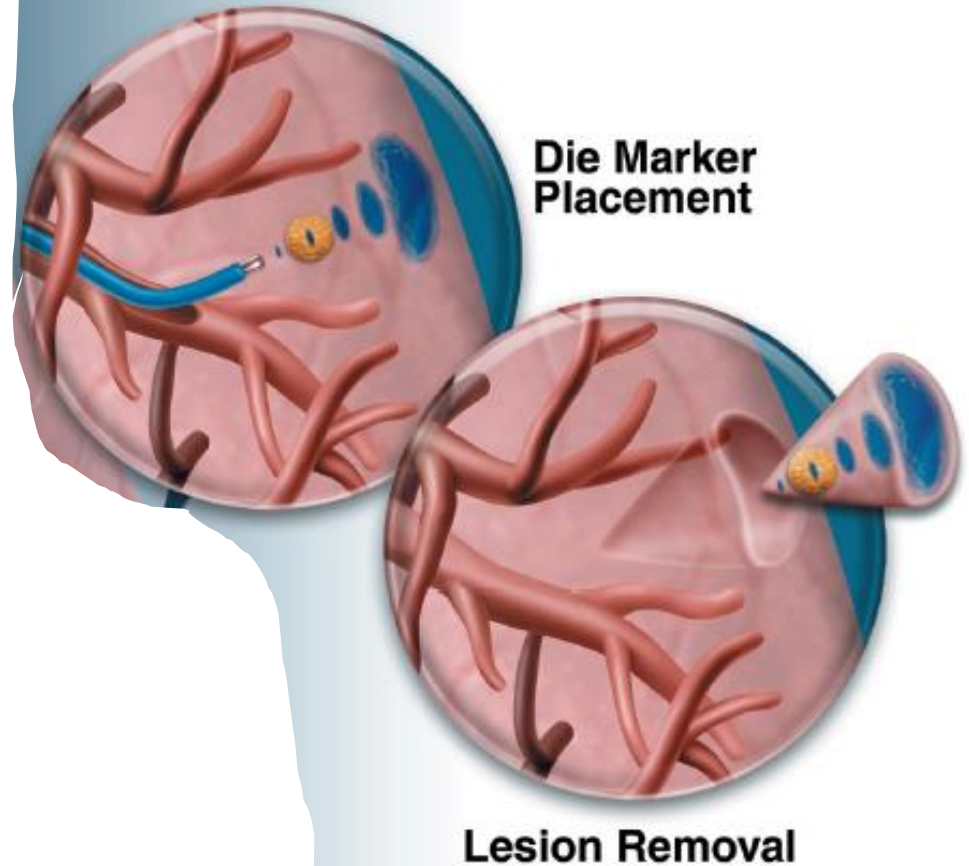
During VATS, the smaller and farther away from the pleura the nodule is, the yield decreases significantly

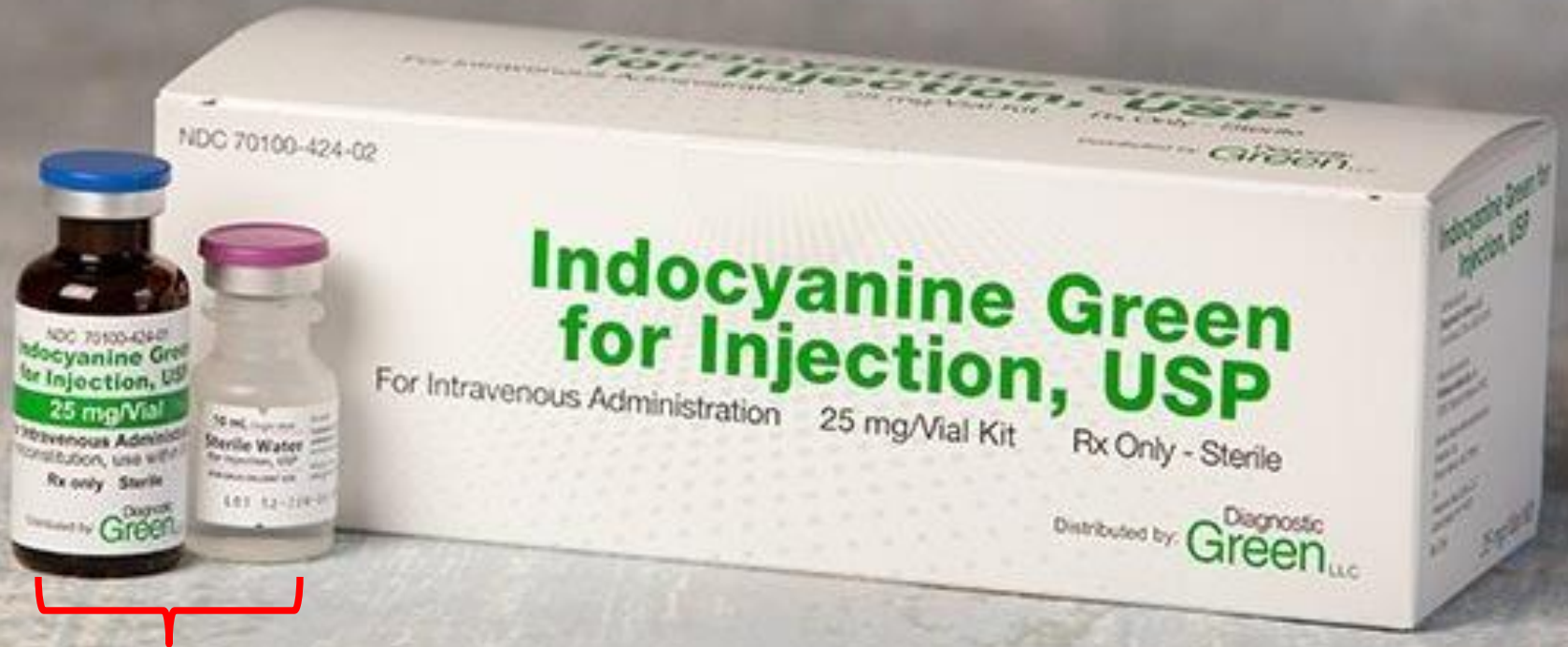	Distance of nodule from pleural surface (mm)			
	0	0-5	5-10	> 10
Nodule size				
< 15 mm	6/8 (75%)	11/17 (65%)	7/14 (50%)	0/15 (0%)
>= 15 mm	10/10 (100%)	13/16 (81%)	5/12 (42%)	2/12 (17%)

Importantly, the tactile feel is completely lost with Robotic approach !!

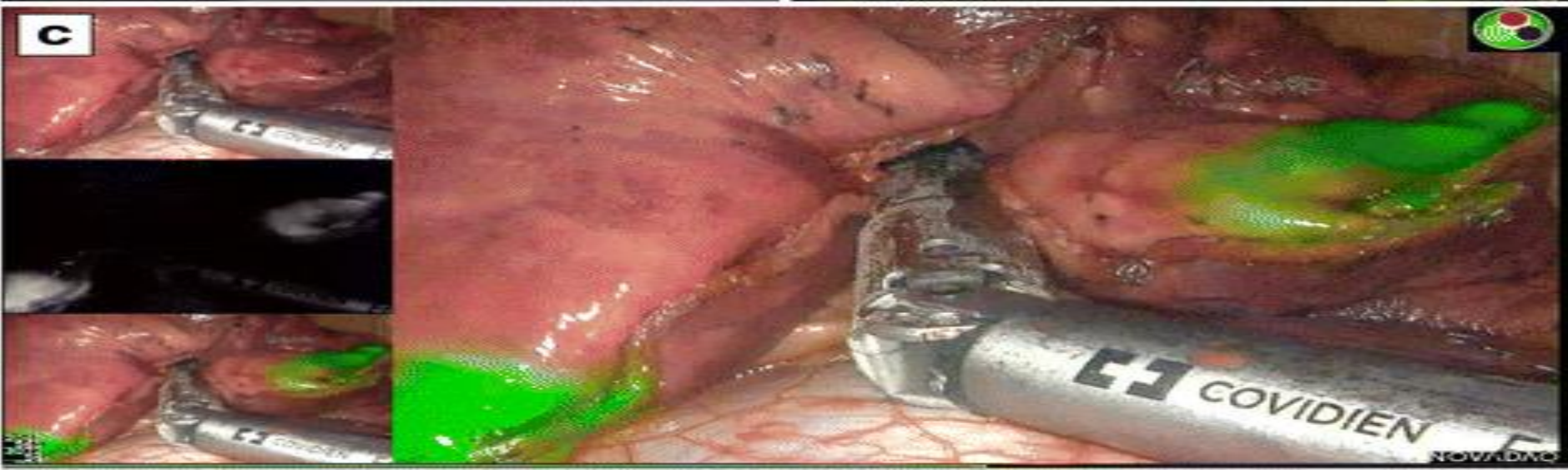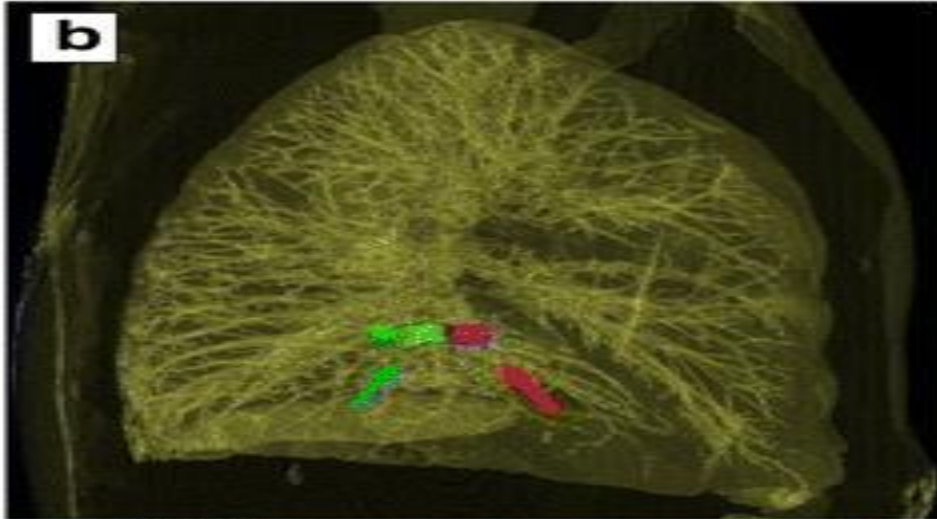



So we mark the lesion with a fluorescent dye, and the surgeon will be able to see it and remove it accurately. All this is done in the same setting





Need to be mixed for the correct concentration for adequate delivery and fluorescence




ARE WE
THERE
YET?



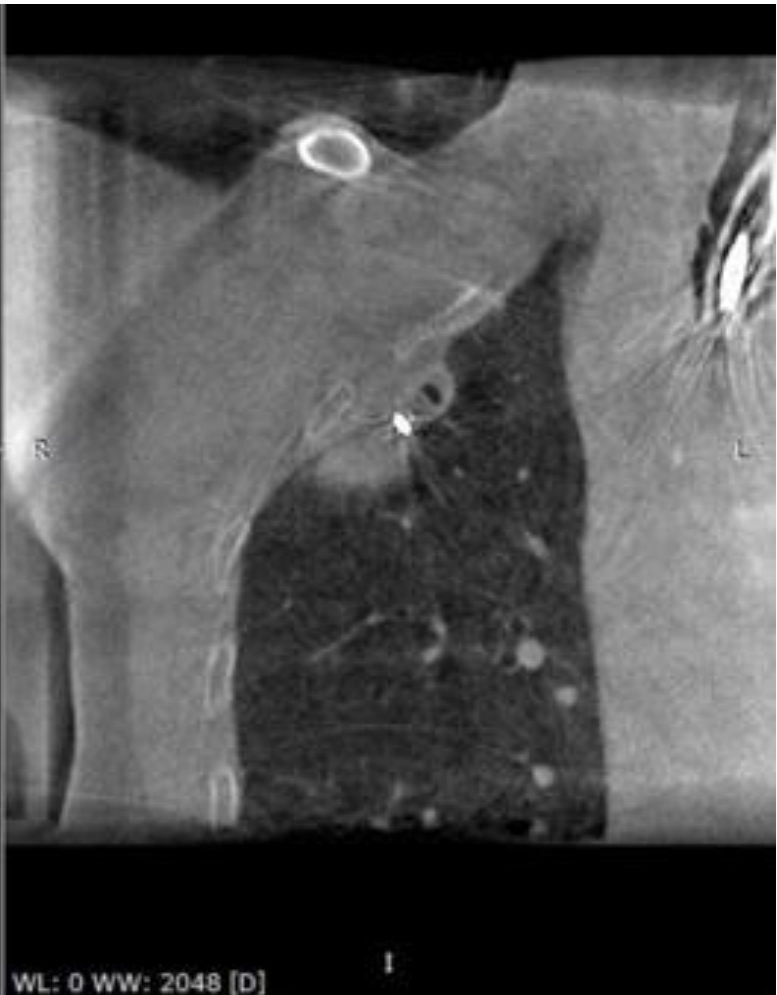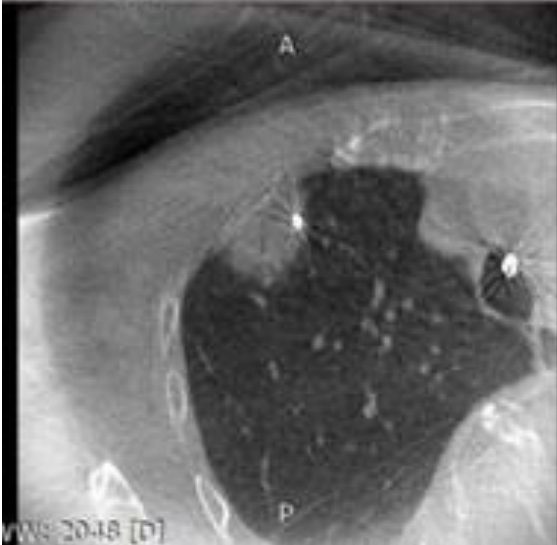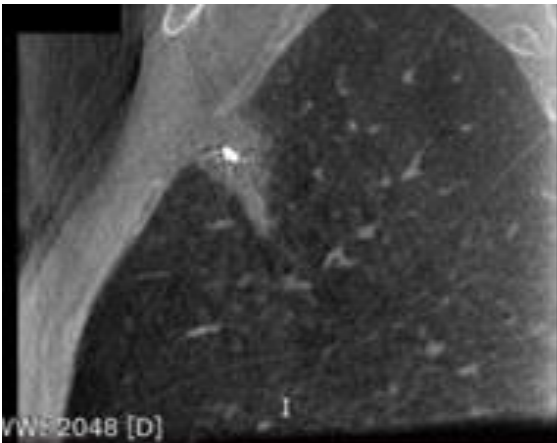
Transbronchial ablation techniques are here.
And YOU play key role in their success



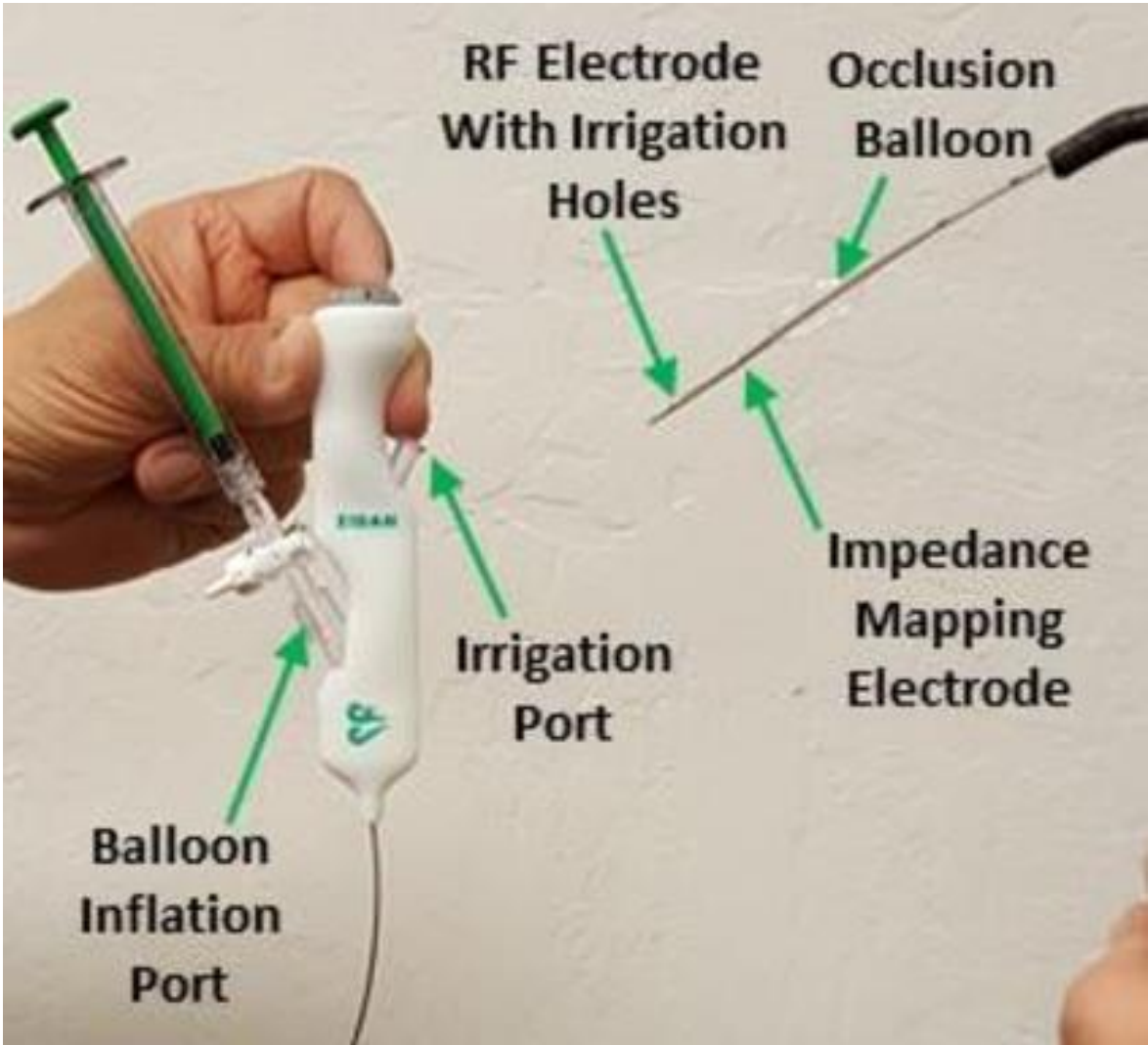
We will use EVA

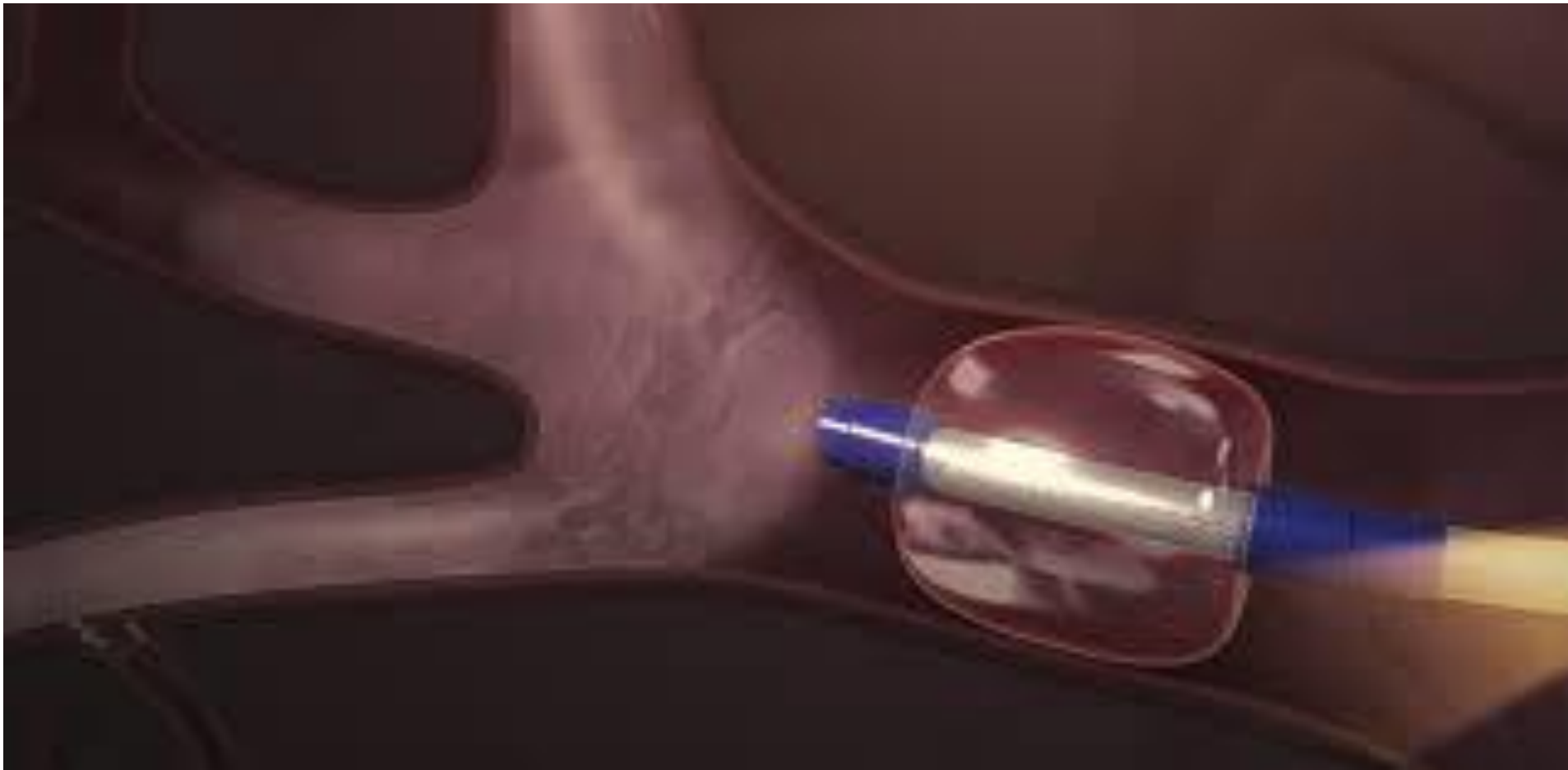


Place the
ablation
catheter
adequately

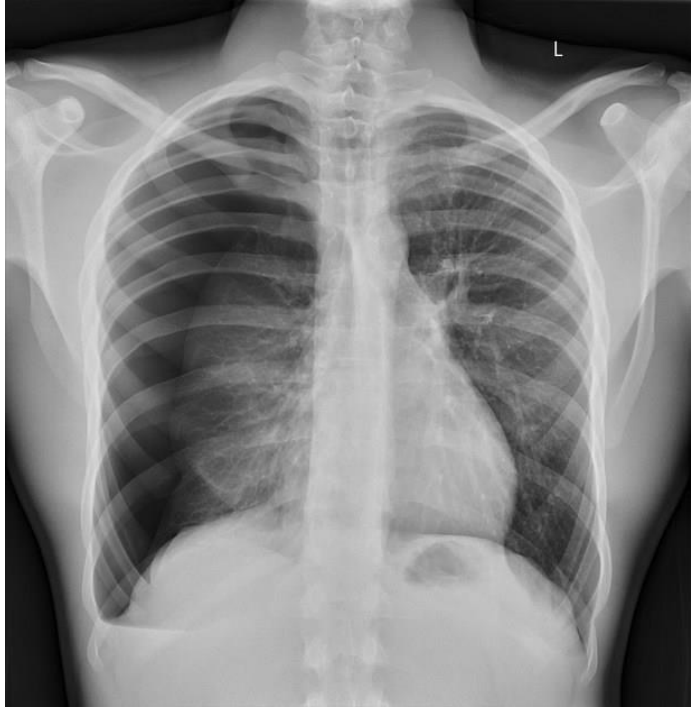

Having knowledge to operate these gadgets is of the utmost importance for the procedure success



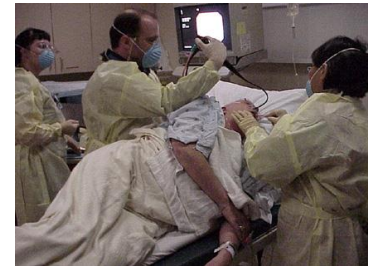

Be aware of the symptoms of significant complications in the procedure suite or recovery



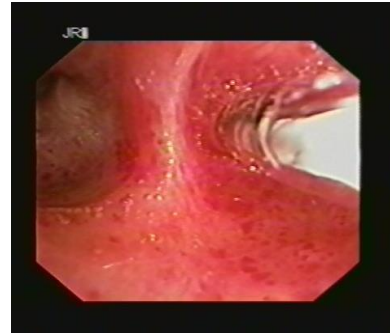
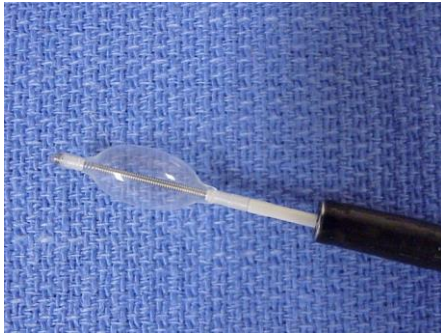Airway bleeding during/post procedure. Please please. If it happens,

- **Bleeding side down** to protect the non-bleeding lung and airways
- Allows blood and secretions to flow from the larynx and out of the corner of the mouth
- Avoids collapse of the larynx and laryngeal obstruction by tongue or edematous upper airway
- **PROTECTS THE CONTRALATERAL AIRWAY**



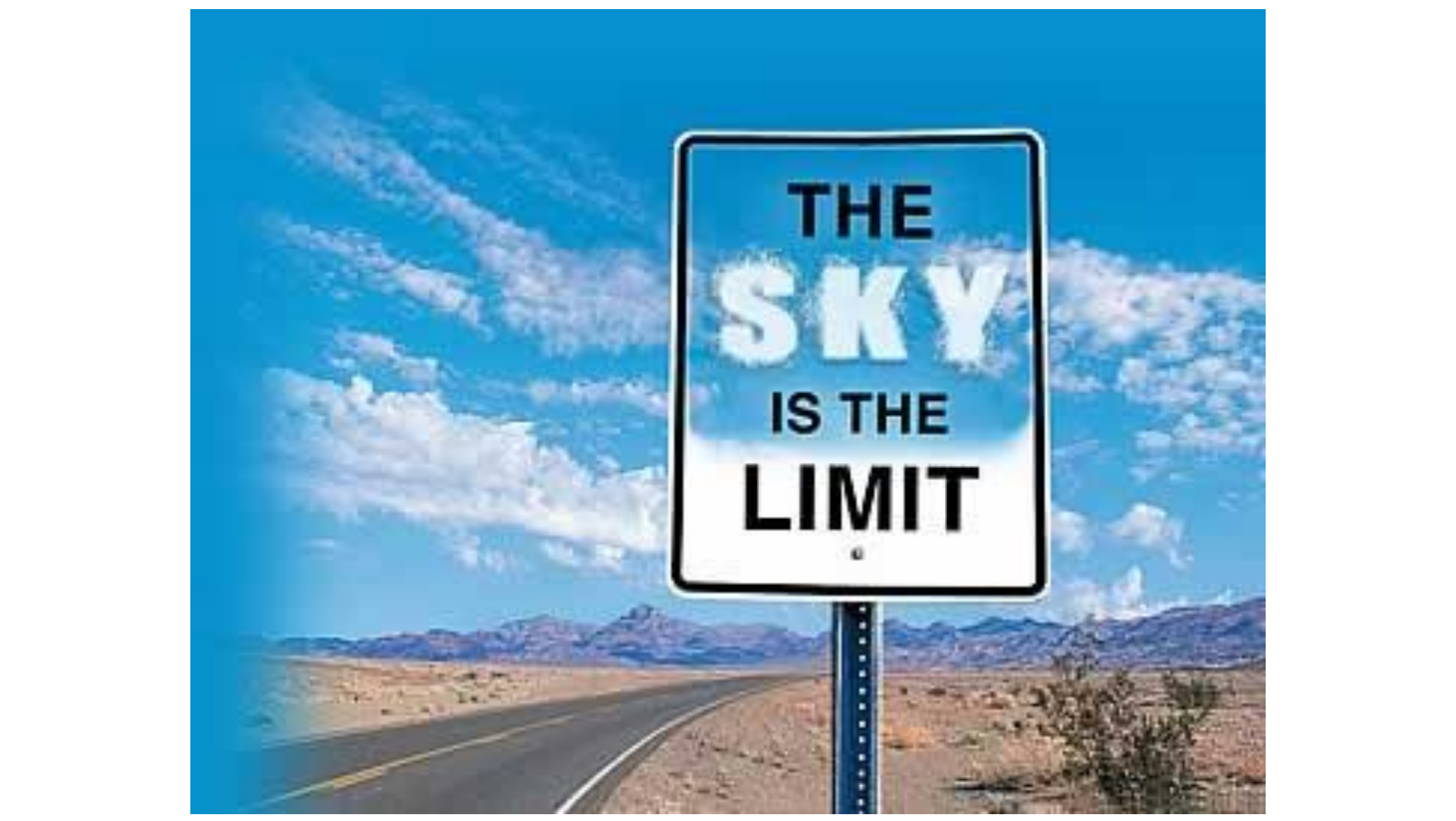
Bronchial Blockers

- Fogarty catheter
 - 8F most commonly used
 - wire stylet to help with guidance/placement
 - can be used to obstruct the segmental bronchi

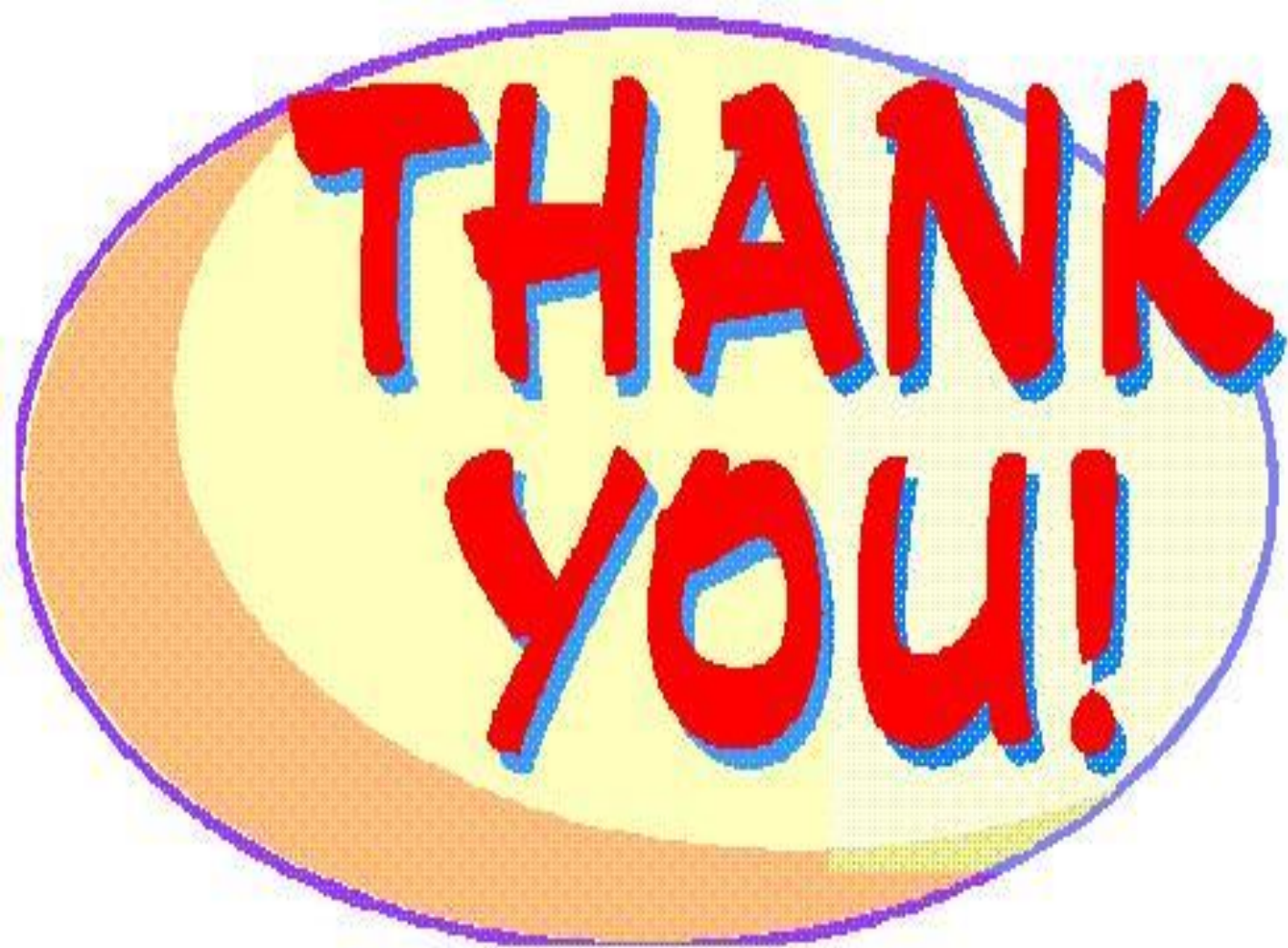

T OGETHER
W E CAN
A CHIEVE
M ORE





**THE
SKY
IS THE
LIMIT**

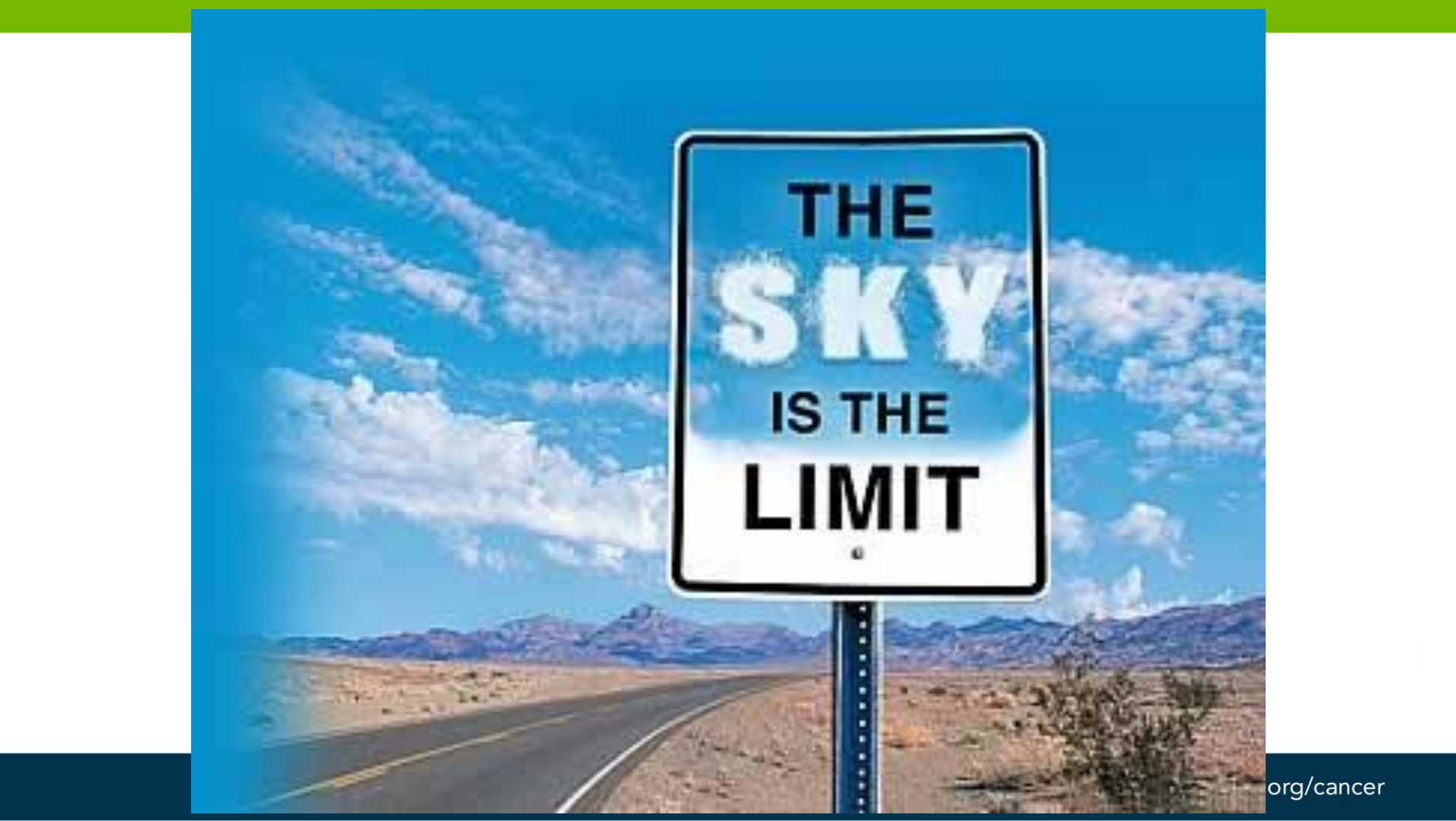


Hell YEAH



FIFA WOMEN'S WORLD CUP 2023™



A photograph of a road sign in a desert landscape. The sign is rectangular with a black border and a white background. It features the text "THE SKY IS THE LIMIT" in bold, black, sans-serif capital letters. The word "SKY" is significantly larger than the other words. The sign is mounted on a blue metal post. The background shows a paved road curving into the distance under a bright blue sky with scattered white clouds. The ground is arid and sandy with some sparse vegetation. In the distance, there are low mountains or hills.

**THE
SKY
IS THE
LIMIT**